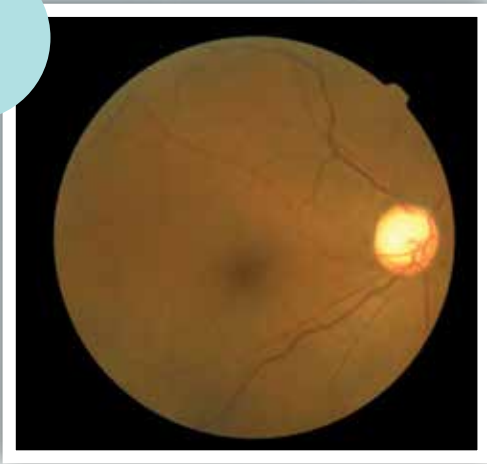


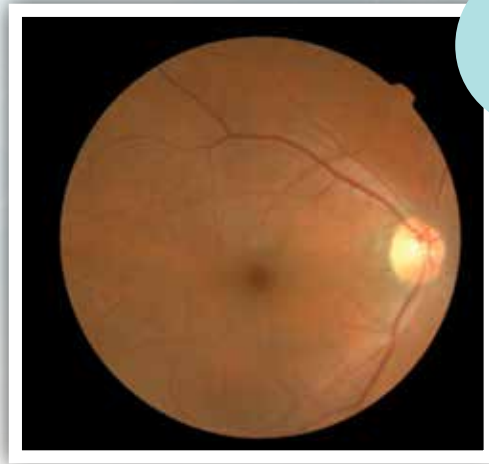
Dr Yeo Kim Teck  
Senior Consultant Ophthalmologist  
Apple Eye Centre

# 'SPOT' DIAGNOSIS IN RETINAL PHOTOGRAPHY

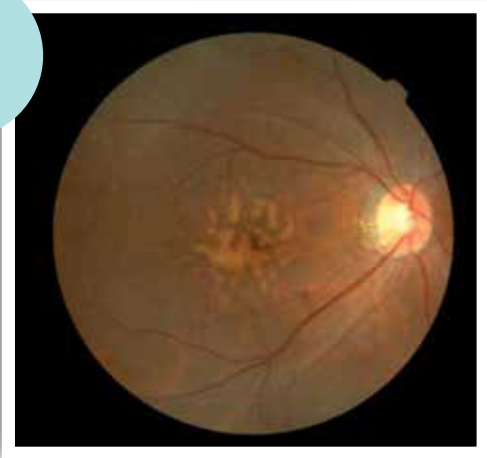1



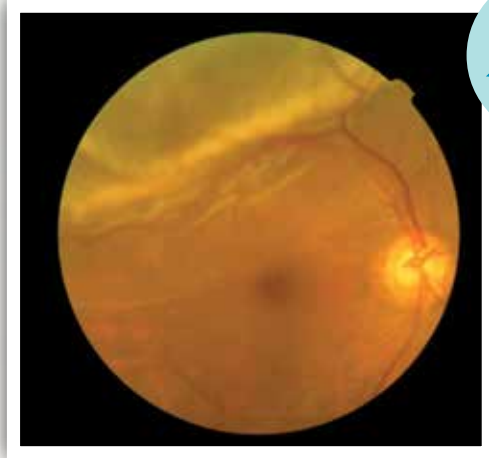
2



3



4



Picture 1  
Normal retina

Picture 2  
Advanced optic disc cupping in late stage chronic glaucoma

Picture 3  
Macular drusen in age-related macular degeneration

Picture 4  
Retinal detachment almost involving the macula

Picture 1  
Normal retina

Picture 2  
Advanced optic disc cupping in late stage chronic glaucoma

Picture 3  
Macular drusen in age-related macular degeneration

Picture 4  
Retinal detachment almost involving the macula